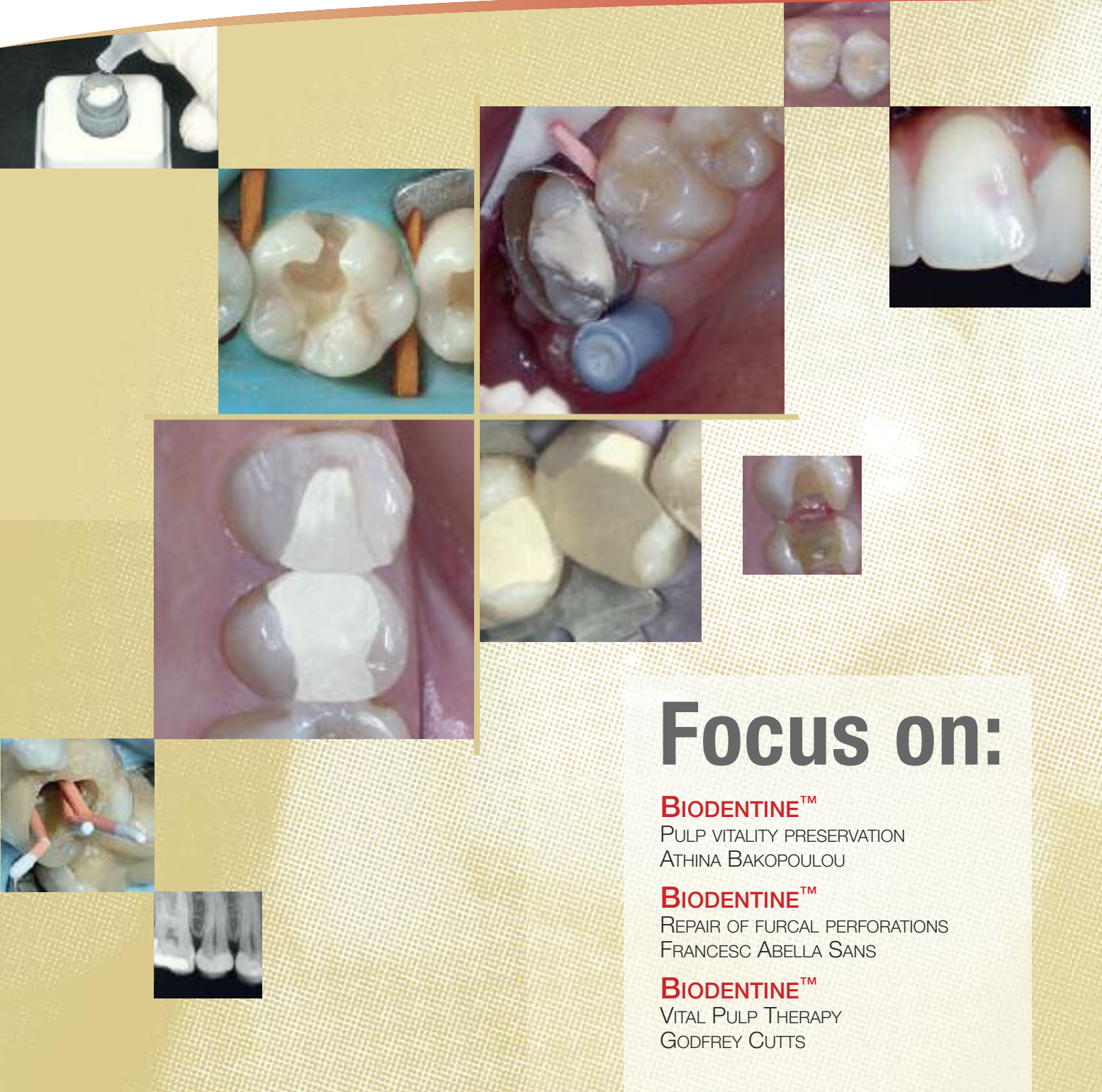


Septodont Case Studies *Collection*

No. 05 - June 2013



Focus on:

BIODENTINE™

PULP VITALITY PRESERVATION
ATHINA BAKOPOULOU

BIODENTINE™

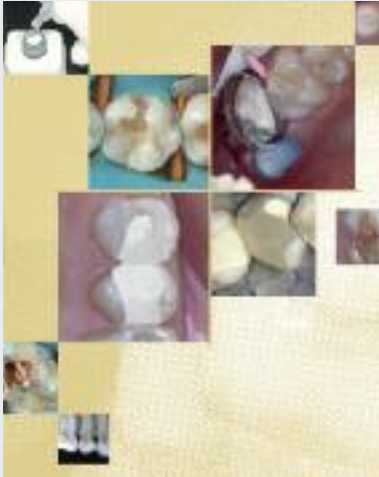
REPAIR OF FURCAL PERFORATIONS
FRANCESCA ABELLA SANS

BIODENTINE™

VITAL PULP THERAPY
GODFREY CUTTS



Editorial



Since its foundation Septodont has developed, manufactured and distributed a wide range of high quality products for dental professionals.

Septodont has recently innovated in the field of gingival preparation, composites and dentin care with the introduction of Racegel, the N'Durance® line and Biodentine™, which are appreciated by clinicians around the globe.

Septodont created the “Septodont Case Studies Collection” to share with you their experience and the benefits of using these innovations in your daily practice.

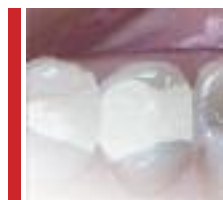This Collection consists in a series of case reports that is published on a regular basis and available as a hard copy or to download from www.septodont.com.

The fifth issue is dedicated to Biodentine™, the first and only dentin in a capsule. Biodentine™ uniqueness not only lies in its innovative bioactive and ‘pulp-protective’ chemistry, but also in its universal application, both in the crown and in the root.

In this issue, you will enjoy 3 case studies articles written by clinicians from 3 countries: Greece, Spain and UK. They focus on the preservation of the pulp vitality and on perforation repair.

They complement the case studies previously published issues and illustrate the worldwide success of Biodentine™.

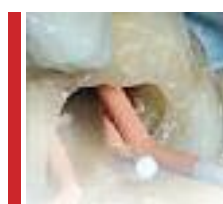Content



Biodentine™ a promising bioactive material for the preservation of pulp vitality in restorative dentistry

Athina Bakopoulou & Imad About

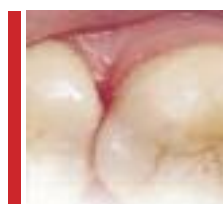04



Biodentine™ as repair material for furcal perforation: 2 case reports

Francesc Abella Sans, Adriana Gómez-Rojas, Guillermo Doria Jaureguizar

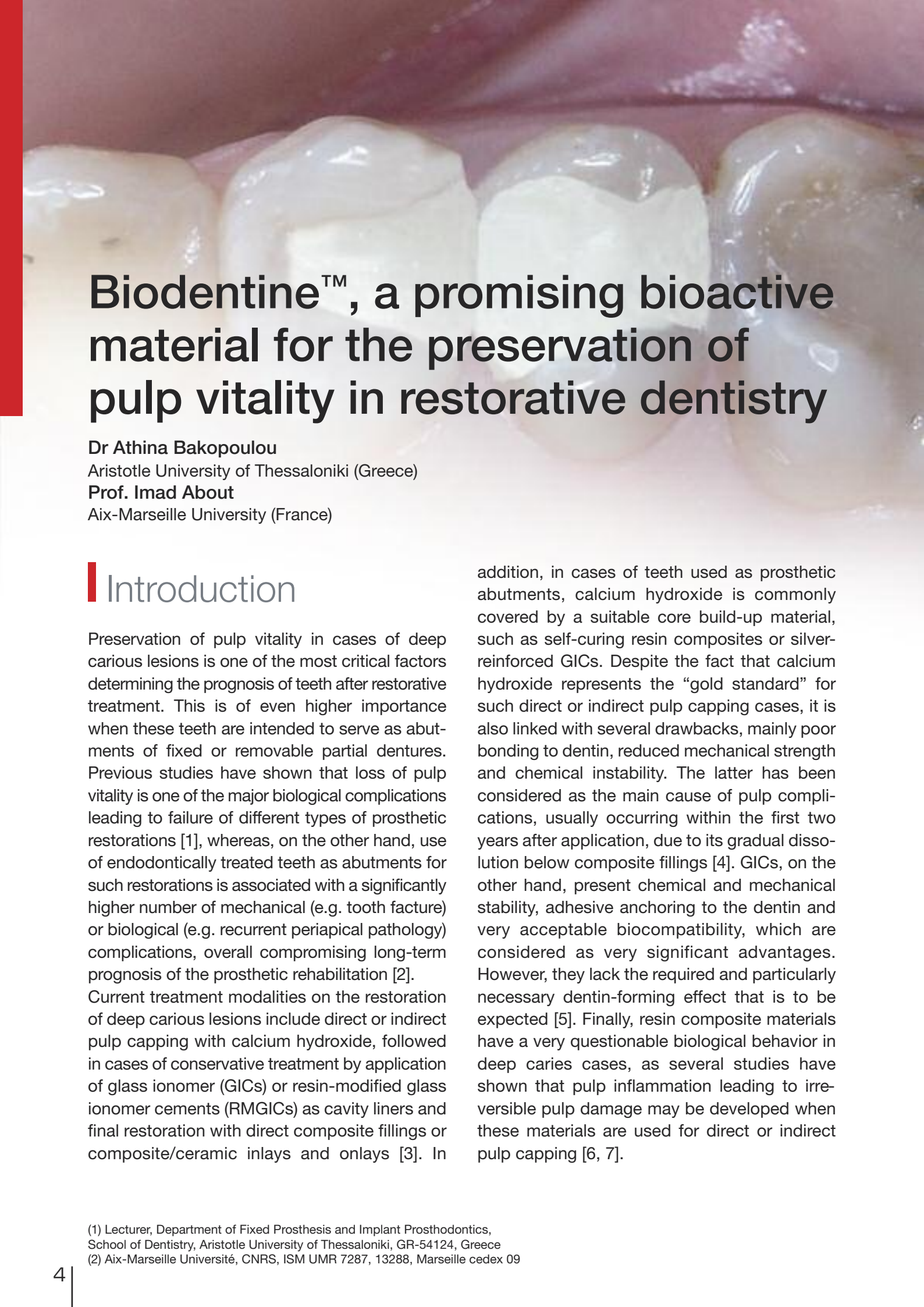
11



Vital Pulp Therapy / Pulp Capping with Biodentine™

Godfrey Cutts

15



Biodentine™, a promising bioactive material for the preservation of pulp vitality in restorative dentistry

Dr Athina Bakopoulou

Aristotle University of Thessaloniki (Greece)

Prof. Imad About

Aix-Marseille University (France)

Introduction

Preservation of pulp vitality in cases of deep carious lesions is one of the most critical factors determining the prognosis of teeth after restorative treatment. This is of even higher importance when these teeth are intended to serve as abutments of fixed or removable partial dentures. Previous studies have shown that loss of pulp vitality is one of the major biological complications leading to failure of different types of prosthetic restorations [1], whereas, on the other hand, use of endodontically treated teeth as abutments for such restorations is associated with a significantly higher number of mechanical (e.g. tooth fracture) or biological (e.g. recurrent periapical pathology) complications, overall compromising long-term prognosis of the prosthetic rehabilitation [2].

Current treatment modalities on the restoration of deep carious lesions include direct or indirect pulp capping with calcium hydroxide, followed in cases of conservative treatment by application of glass ionomer (GICs) or resin-modified glass ionomer cements (RMGICs) as cavity liners and final restoration with direct composite fillings or composite/ceramic inlays and onlays [3]. In

addition, in cases of teeth used as prosthetic abutments, calcium hydroxide is commonly covered by a suitable core build-up material, such as self-curing resin composites or silver-reinforced GICs. Despite the fact that calcium hydroxide represents the “gold standard” for such direct or indirect pulp capping cases, it is also linked with several drawbacks, mainly poor bonding to dentin, reduced mechanical strength and chemical instability. The latter has been considered as the main cause of pulp complications, usually occurring within the first two years after application, due to its gradual dissolution below composite fillings [4]. GICs, on the other hand, present chemical and mechanical stability, adhesive anchoring to the dentin and very acceptable biocompatibility, which are considered as very significant advantages. However, they lack the required and particularly necessary dentin-forming effect that is to be expected [5]. Finally, resin composite materials have a very questionable biological behavior in deep caries cases, as several studies have shown that pulp inflammation leading to irreversible pulp damage may be developed when these materials are used for direct or indirect pulp capping [6, 7].

(1) Lecturer, Department of Fixed Prosthesis and Implant Prosthodontics, School of Dentistry, Aristotle University of Thessaloniki, GR-54124, Greece

(2) Aix-Marseille Université, CNRS, ISM UMR 7287, 13288, Marseille cedex 09

For all these reasons, there is a need for a new bioactive pulp capping material ensuring the long-term preservation of pulp vitality after restorative treatment of deep carious lesions. Most recently, a calcium-silicate based cement (Biodentine™, Septodont) has been proposed -among other clinical applications- as a dentin substitute for direct and indirect pulp capping. As main advantages of this material have been reported its ability to create a firm anchorage to dentin, its bioactivity leading to reparative dentin formation, its antibacterial properties which are highly required in deep carious lesions and its improved mechanical properties, which are similar to dentin [8]. Here we present two clinical cases of successful use of Biodentine™ in deep carious lesions of patients with a previous history of pulp complications after restoration of deep caries with conventional protocols.

Case Report no. 1

A 38 year-old female patient, with free medical history, came complaining for tooth sensitivity at the upper right maxilla, after consuming cold and hot beverages. Diagnostic assessment and radiographical examination revealed secondary carious lesions below existing amalgam restorations in teeth # 14 (distally) and # 15 (interproximally) (Fig. 1). Both teeth were tested positive on CO₂ snow sensitivity and negative on percussion. The patient was informed about the need of having the carious lesions treated and the amalgam fillings replaced.

After patient consent, local anesthesia was performed (Articaine HCL 4% and 1:200000 adrenaline, Ubistesin, 3M ESPE), the amalgam restorations were removed and the carious dentin was completely excavated (Fig. 2). At the proximal cavity area of tooth # 15 a very thin pulp facing layer of remaining dentin could be observed (Fig. 3). Biodentine™ (Septodont) was chosen as a provisional filling material of the entire cavity of both teeth (Fig. 4, 5). The material was handled according to the manufacturer's

instructions. This decision to use Biodentine™ was based on a previous history of unsuccessful outcome of indirect pulp capping after caries removal in teeth # 24 and 25 of the same patient, by using calcium hydroxide capped by a GIC as a cavity liner and final restoration with resin composites, which resulted to irreversible pulp inflammation 2 months after restoration. Biodentine™ was left in place for 6 weeks in order to ensure that pulp sensitivity would be

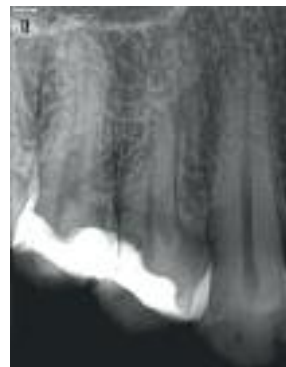

Fig. 1: Preoperative radiograph showing recurrent caries below existing amalgam restorations in teeth # 14 and 15

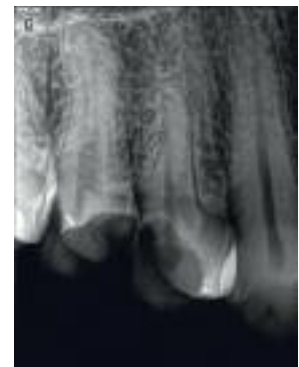

Fig. 2: Radiograph taken after caries removal, showing close proximity of the cavity walls to the pulp, especially for tooth # 15

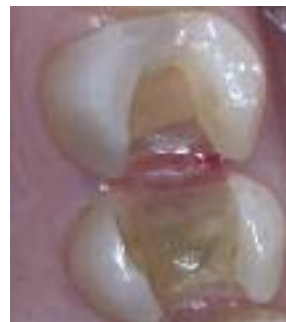

Fig. 3: Clinical picture after caries removal

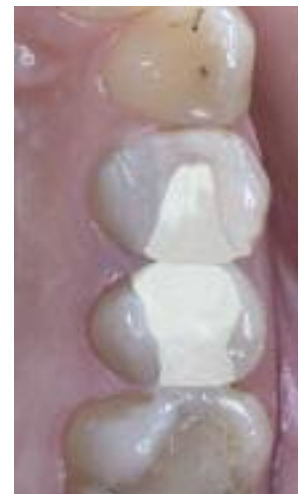

Fig. 4: Biodentine™ was placed as a bulk material to restore both cavities and left in place for 6 weeks. The material has a smooth surface after setting.

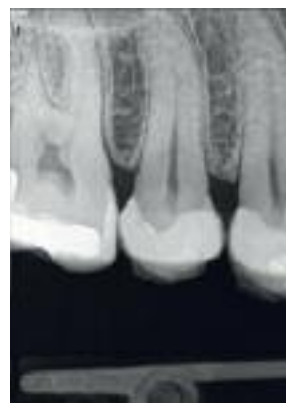

Fig. 5: Radiograph after Biodentine™ placement.

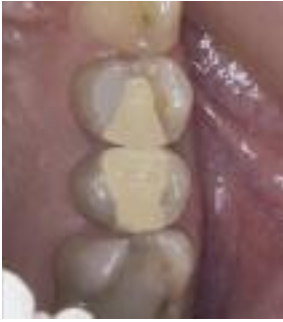

Fig. 6: Biodentine™ restorations 6 weeks after placement. Marginal integrity of both restorations was fully preserved and no fractures were observed. A slight discoloration of both restorations could be recorded.

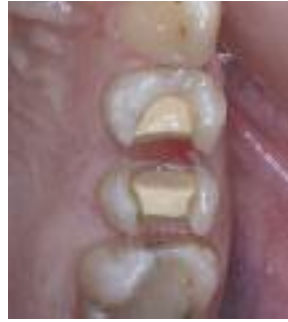

Fig. 7: Biodentine™ was partially removed to serve as a dentin substitute.

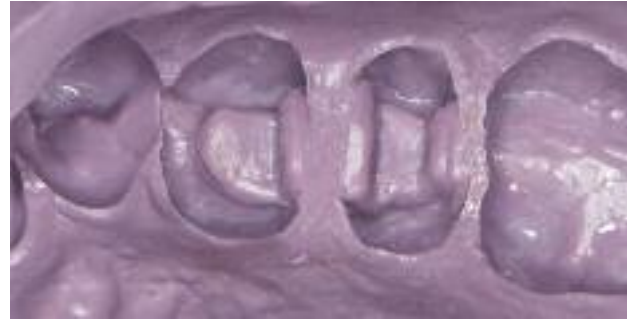

Fig. 8: Final impression with one-phase polyether material.

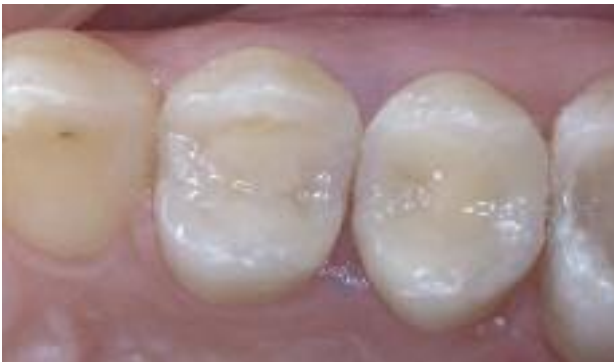

Fig. 10: Final inlay restorations in place cemented with a dual cure resin cement.

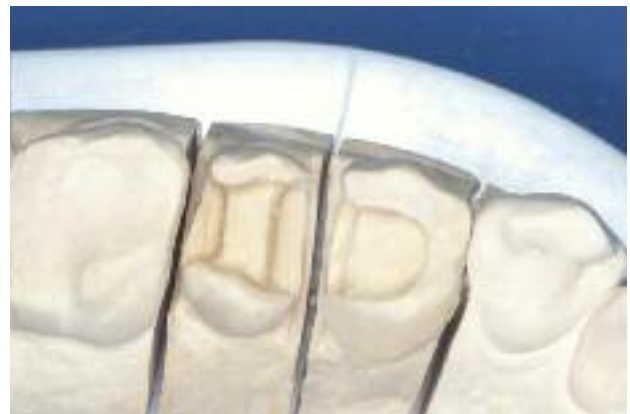

Fig. 9: Final cast for the inlays build up with a laboratory composite.

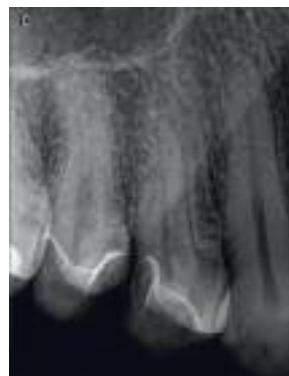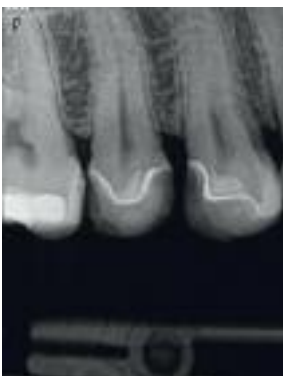


Fig. 11: A, B Radiograph A. six months and B. 1 year post-treatment.

eliminated while preserving pulp vitality (*Fig. 6*). The patient reported that she remained symptom-free during the six week period, whereas both teeth were positive on CO₂ snow sensitivity and negative on percussion. Biodentine™ was then partially removed to serve as a cavity liner (*Fig. 7*) and both teeth were restored with indirect composite restorations. Briefly, after final cavity preparation with Biodentine™ remaining as a dentin substitute, final impression was taken using a one-phase polyether material (Impregum, 3M ESPE) (*Fig 8, 9*). The teeth were restored with composite inlays (SR Adoro, Ivoclar Vivadent) that were cemented with a dual cure resin cement (Variolink II, Ivoclar Vivadent) (*Fig. 10*). At the follow-up visit at 6 months and 1 year after treatment (*Fig. 11 A, B*) both teeth were free from any symptomatology and again tested positive for sensitivity and negative for percussion. Radiographical examination showed no signs of periapical pathology (*Fig. 11 B*).

Case Report no.2

A 28 year-old female patient, with free medical history, came after fracture of her first upper left molar (# 26), which occurred during chewing (Fig. 12). Clinical and radiographical examination revealed deep caries at a very high proximity to the pulp in both upper molars (# 26 and # 27) (Fig. 13). Tooth # 26 had already a composite resin filling that was placed 2 years earlier. Clinical examination also showed that both teeth were positive on CO₂ snow sensitivity and negative on percussion. The patient did not mention any previous symptomatology derived from these teeth in her dental history. However, she mentioned that her two lower molars (# 36 and # 46) were endodontically treated due to deep caries that were symptom-free and therefore could not be diagnosed until they reached the pulp cavity. The patient was informed about the need of having the carious lesions treated and the possibility that an endodontic treatment would be required after caries removal.

After patient consent, local anesthesia was performed (Articaine HCL 4% and 1:200000 adrenaline, Ubistesin, 3M ESPE) and a rubber dam was placed to avoid contamination with saliva in case a pulp exposure would occur. After excavation of the carious dentin, the pulp was exposed iatrogenically in tooth # 26, whereas a very thin pulp facing layer of dentin could be observed in the distal area of 26, as well as the proximal area of 27, both requiring indirect pulp capping (Fig. 14, 15). Clinically the pulp of the tooth # 26 at the exposure site was vital without any major bleeding, so the maintenance of tooth vitality by direct pulp capping was decided upon. Cavity disinfection and control of the hemorrhage in tooth # 26 was performed with sodium hypochloride. Biodentine™ (Septodont) was chosen as a provisional filling material of the entire cavity of both teeth (Fig. 16). The material was handled according to the manufacturer's instructions. Biodentine™ was left in place for 6 weeks after which the patient came to receive her final restorative treatment (Fig. 17). During this period of 6 weeks the patient was symptom-free, whereas

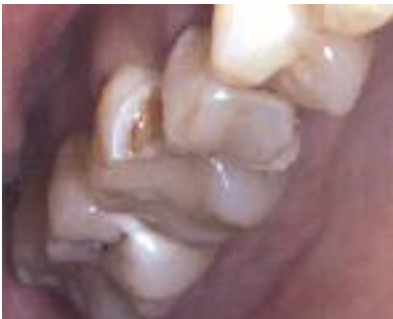

Fig. 12: Preoperative clinical picture showing fracture of tooth # 26
Preoperative radiograph showing deep caries in teeth # 26 and 27 in close proximity to the pulp

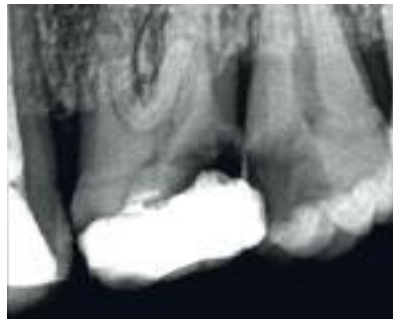


Fig. 13: Preoperative radiograph

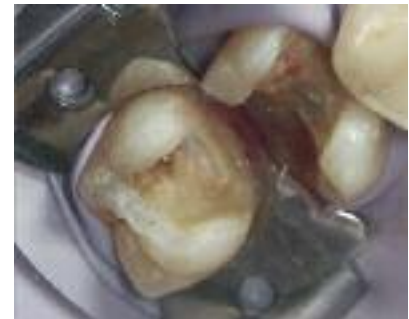

Fig. 14: After caries removal the pulp was exposed iatrogenically in tooth # 26, whereas a very thin pulp facing layer of dentin could be observed in the distal area of 26, as well as the proximal area of 27.

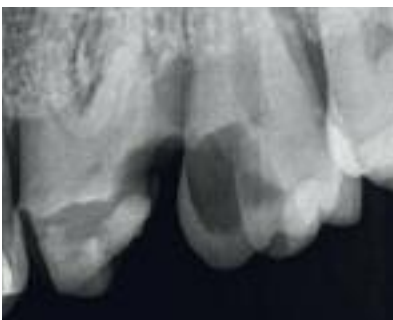


Fig. 15: Radiograph after caries removal

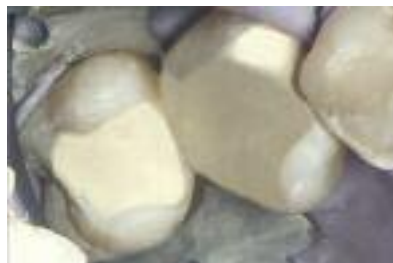

Fig. 16: Biodentine™ was placed as a bulk material to restore both cavities and left in place for 6 weeks. A rubber dam was used to avoid bacterial contamination after pulp exposure

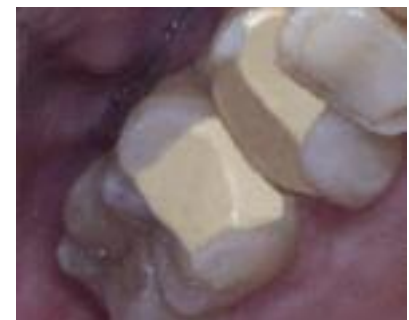

Fig. 17: Biodentine™ restorations after 6 weeks of placement. Marginal integrity of both restorations was fully preserved and no fractures were observed.

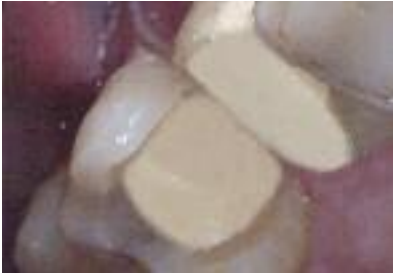

Fig. 18: In tooth # 27 Biodentine™ was then partially removed and kept as a base/dentin substitute that was capped by a direct composite resin filling (Tetric EvoCeram, Ivoclar-Vivadent). Tooth # 26 was prepared for full coverage and Biodentine™ remained as an abutment build-up material.

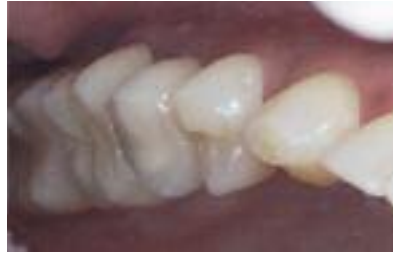

Fig. 19: Post-operative clinical picture with a direct resin composite filling in tooth # 27 and a metal ceramic crown in tooth # 26.

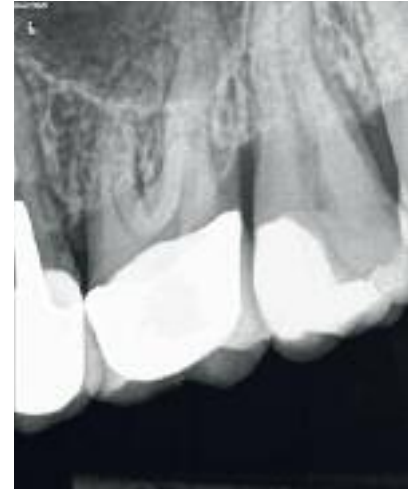

Fig. 20: Radiograph six months post treatment. No signs of periapical pathology could be observed

both teeth remained positive on CO₂ snow sensitivity and negative on percussion. Biodentine™ was then partially removed in tooth # 27 and kept as a base/dentin substitute that was capped by a direct composite resin filling (Tetric EvoCeram, Ivoclar-Vivadent), following normal procedures (acid etching of the cavity with phosphoric acid and application of single step adhesive of the same company) (Fig. 18, 19). Tooth # 26, on the other hand was prepared for a full coverage metal-ceramic crown due to the

significant loss of dental hard tissues after caries removal. The tooth was prepared without removing Biodentine™ that remained and served as an abutment core build-up material (Fig 18). The final metal-ceramic crown was cemented with a conventional GIC (Fuji I, GC) (Fig. 19). At the follow-up visit after 6 months both teeth were free from any symptomatology and again tested positive for sensitivity and negative for percussion. Radiographical examination showed no signs of periapical pathology (Fig. 20).

Discussion

Biodentine™ is a bioactive material mainly composed of tricalcium silicate and a radiopacifier phase of zirconium oxide. Calcium silicate-based cements are known to release during setting and for a long period of time thereafter significant amounts of calcium hydroxide ions, responsible for triggering pulp reparative processes [9]. Histological studies have shown the formation of a homogeneous dentin bridge at the pulp exposure site after direct or indirect capping with Biodentine™ [10, 11]. Mineralized tissue formation was found to express markers of odontoblasts [12]. The ability of Biodentine™ to trigger reparative dentin formation together with its antibacterial properties are two critical factors ensuring long-term preservation of pulp vitality. While the antibacterial activity may be due to the alkaline pH, the induction of reparative

dentin seems to be due to a release of TGF-β1 growth factor from pulp cells. This factor attracts pulp stem cells to Biodentine™ application site where it induces their differentiation into odontoblastic cells secreting reparative dentin [13]. The resulting pulp vitality preservation is highly required in restorative dentistry, especially when the restored teeth will be used as abutments of long-span prosthetic restorations.

Compared to conventionally used pulp capping materials, such as calcium hydroxide, Biodentine™ presents significantly higher mechanical properties which are very similar to those of dentin (elastic modulus of 22 GPa, compressive strength of 220 MPa and microhardness of 60 VHN) [14]. This allows the preservation of the material as a base underneath resin fillings or even its use as a core-build up material in vital

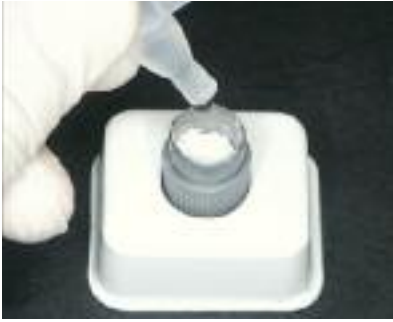

Fig. 21, 22, 23: The material should be handled according to the manufacturer's instructions. It is important to add exactly 5 drops of liquid into the powder capsule and allow it to mix at a speed of 4000 – 4200 rotations/min for 30 seconds.

abutment teeth. Moreover, the ability of the material to create a firm bond with the underlying dentin substrate is highly required for core build-up materials, to ensure the preservation of the abutment integrity and therefore to lower the risk for crown or bridges detachment. Future studies are, however, required to evaluate the behavior of Biodentine™ as a core build-up material of vital abutment teeth in long-span fixed partial dentures, especially in teeth that serve as terminal abutments for such restorations that are normally subjected to higher masticatory forces.

Although the handling properties of the material present some difficulties, this can be easily overcome by strict compliance to the manufacturer's instructions. It is important to add exactly 5 drops of liquid into the powder capsule and allow it to mix at a speed of 4000 - 4200 rotations/min for 30 seconds (*Fig. 21-23*). In case a lower amount of liquid is added the material is very dry and brittle, whereas a higher amount of liquid will give the material a runny consistency making its handling very difficult. Correctly mixed material must have a creamy consistency (*Fig. 24*). It is also important to allow Biodentine™ to set for at least 12 min before matrix band and wedge

removal (*Fig. 25*), otherwise the risk of material fracture is very high. Biodentine™ should not come in contact with liquids during its setting and for this reason application of a rubber dam is mandatory whenever possible. Moreover, the material should be applied into the cavity with light pressure, avoiding excessive carving of the restoration during its setting, because this may disturb its crystalline structure and lead to loss of marginal integrity or fracture. Finally, occlusal adjustment after the material's setting should be performed by light biting on occlusion paper and premature contact removal by a curving hand instrument or excavator and not by rotary instruments.

In conclusion, Biodentine™ seems to be a very promising material for the preservation of pulp vitality in cases of deep caries. It has a unique set of properties which are highly desirable in restorative dentistry and prosthodontics. Randomized control clinical trials substantiate the improved clinical performance of this new bioactive material compared to conventionally applied treatment protocols. However, other randomized clinical trials are needed to confirm the clinical performance of this new dentin substitute.



Fig. 24: Correctly mixed material must have a creamy consistency

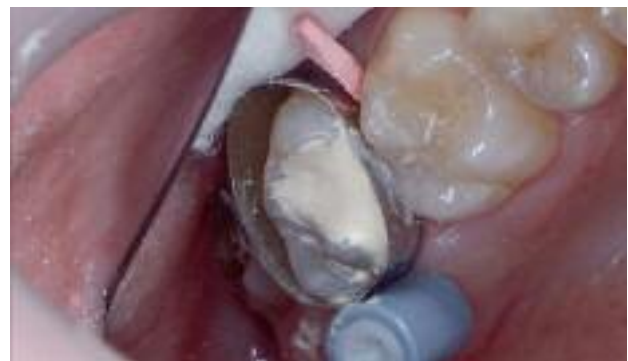

Fig. 25: It is important to allow Biodentine™ to set for 12-15 min before matrix band and wedge removal

References

01. Sailer I, Pjetursson BE, Zwahlen M, Hämmerle CH. A systematic review of the survival and complication rates of all-ceramic and metal-ceramic reconstructions after an observation period of at least 3 years. Part II: Fixed dental prostheses. *Clin Oral Implants Res.* 2007;18 Suppl 3:86-96.
02. De Backer H, Van Maele G, De Moor N, Berghe L. Long-term results of short-span versus long-span fixed dental prostheses: an up to 20-year retrospective study. *Int J Prosthodont* 2008;21:75-85.
03. Fransson H. On the repair of the dentin barrier. *Swed Dent J Suppl.* 2012;(226):9-84
04. Al-Hiyasat AS, Barrieshi-Nusair KM, Al-Omari MA. The radiographic outcomes of direct pulp-capping procedures performed by dental students. A retrospective study. *J Am Dent Assoc* 2006;137: 1699–1705.
05. Weiner RS, Weiner LK, Kugel G. Teaching the use of bases and liners: a survey of North American dental schools. *J Am Dent Assoc.* 1996;127(11):1640-5.
06. da Silva LA, de Freitas AC, de Carvalho FK, de Queiroz AM, Nelson-Filho P, Porto-Neto ST. Direct pulp capping with a self-etching adhesive system: histopathologic evaluation in dogs' teeth. *Oral Surg Oral Med Oral Pathol Oral Radiol Endod* 2009;108(1):34-40.
07. de Souza Costa CA, Teixeira HM, Lopes do Nascimento AB, Hebling J. Biocompatibility of resin-based dental materials applied as liners in deep cavities prepared in human teeth. *J Biomed Mater Res B Appl Biomater.* 2007;81(1):175-84.
08. Koubi G, Colon P, Franquin JC, Hartmann A, Richard G, Faure MO, Lambert G. Clinical evaluation of the performance and safety of a new dentin substitute, Biodentine™, in the restoration of posterior teeth - a prospective study. *Clin Oral Investig.* 2013;17(1):243-9.
09. Gandolfi MG, Ciapetti G, Perut F, Taddei P, Modena E, Rossi PL, Prati C. Biomimetic calcium-silicate cements aged in simulated body solutions. Osteoblast response and analyses of apatite coating. *J Appl Biomater Biomech.* 2009;7(3):160-70.
10. Shayegan A, Jurysta C, Atash R, Petein M, Abbeele AV. Biodentine™ used as a pulp-capping agent in primary pig teeth. *Pediatr Dent.* 2012;34(7):202-8.
11. Tran XV, Gorin C, Willig C, Baroukh B, Pellat B, Decup F, Opsahl Vital S, Chaussain C, Boukpepsi T. Effect of a calcium-silicate-based restorative cement on pulp repair. *J Dent Res.* 2012;91(12):1166-71.
12. Laurent P, Camps J, About I. Biodentine™ induces TGF-β1 release from human pulp cells and early dental pulp mineralization. *Int Endod J.* 2012;45(5):439-48.
13. Mathieu S, Jeanneau C, Sheibat-Othman N, Kalaji N, Fessi H, About I. Usefulness of Controlled Release of Growth Factors in Investigating the Early Events of Dentin-pulp Regeneration. *J Endod.* 2013; 39(2):228-35.
14. Grech L, Mallia B, Camilleri J. Investigation of the physical properties of tricalcium silicate cement-based root-end filling materials. *Dent Mater.* 2012 [Epub ahead of print]



Author: Dr. Athina Bakopoulou

Dr. Athina Bakopoulou is a Lecturer at the Department of Fixed and Implant Prosthodontics at the School of Dentistry of the Aristotle University of Thessaloniki. Since 2009 she is a Visiting Research Fellow at the Department of Conservative Dentistry, Periodontology and Preventive Dentistry of the Center of Oral and Maxillofacial Sciences of the Hannover Medical School in Germany. She graduated from the National and Kapodistrian University of Athens in 2000 and subsequently followed a 3-year postgraduate program in Prosthodontics (2001-2004) and a 3-year PhD program (2004-2007) at the University of Thessaloniki. She has already significant published work in peer-review journals in the field of prosthetic rehabilitation, biocompatibility of dental restorative materials and dental tissue engineering and she has presented her research and clinical work in more than 50 international and national meetings and conferences, where she has been the recipient of significant awards, including the first award for “outstanding poster presentation” at the 11th (Crete, Greece, 2005) and the 12th (Fukuoka, Japan, 2007) Biannual Meeting of the International College of Prosthodontists (ICP), as well as the first Senior Robert Frank Award for Basic Research at the 44th IADR-CED Meeting (Munich, Germany, 2009).

Biodentine™ as repair material for furcal perforation: 2 case reports

Dr Adriana Gómez-Rojas, Dr Guillermo Doria Jaureguizar, Dr Francesc Abella Sans
Universitat Internacional de Catalunya (Spain)

Several new calcium silicate-based materials have recently been developed (1-3) that aim to overcome the drawbacks of mineral trioxide aggregate (MTA), such as its difficult handling properties (4), potential discoloration (5), and long setting time (6, 7). Biodentine™ (Septodont, Saint-Maur-des-Fossés, France), a silicate-based material that is used as a dentin restorative material, also has endodontic indications similar to those of MTA. Unlike Portland cements, Biodentine™, with its improved physical properties (8, 9) and shorter setting time (12-min) (8), can be used as a dentin substitute in several clinical indications. Biodentine™ has emerged as a reliable bioactive material with various applications in endodontics that include obturation combined with root-end resection, apexification, root perforations, and in cases of internal resorption and dens in dente. We describe two clinical cases performed with the application of Biodentine™ in order to introduce clinicians to an alternative treatment strategy in teeth with furcal perforations.

Case Report no.1

A 54-year old female patient was referred to the Department of Restorative Dentistry and Endodontics at the Universitat Internacional de Catalunya (St Cugat del Vallès, Barcelona, Spain) for endodontic retreatment of the maxillary right first molar (tooth # 3), with history of pain. The general anamnesis contained no abnormal data. Episodes of pain were found in the dental history. On examination the tooth was painful to percussion. Palpation of the buccal and palatal aspect of the tooth revealed no tenderness. The tooth was not mobile and periodontal probing around it was within physiological limits. The preoperative diagnosis radiograph of

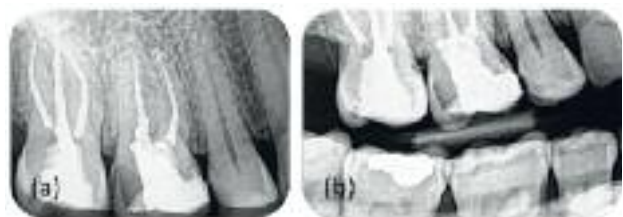

Fig. 1: (a) Periapical radiograph of tooth #3 revealed a previous endodontic treatment and a possible missed disto-buccal root canal. (b) Bite-wing radiograph provided more precise information about the condition of the pulp chamber.

tooth # 3 revealed composite restoration, previous endodontic treatment with no signs of periapical radiolucency, and a possible missed root canal in the distal root (*Fig. 1a, b*). Based on the clinical and radiographic findings, symptomatic apical periodontitis was diagnosed and endodontic retreatment scheduled.

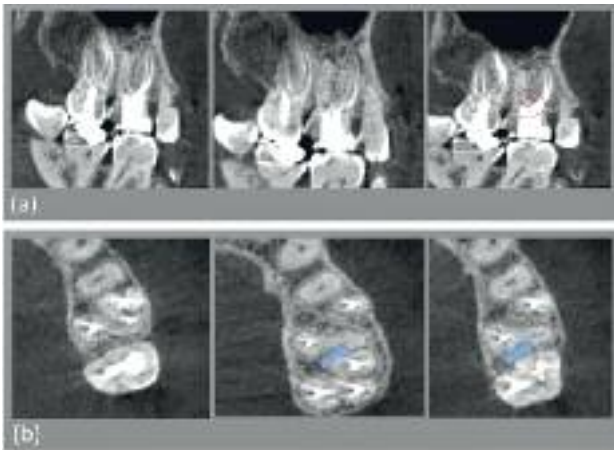


Fig. 2: Small volume CBCT scan (ProMax 3Ds; Planmeca OY, Helsinki, Finland). (a) Coronal views showed an untreated disto-buccal root canal, a periapical lesion associated with the distal root, and a furcal perforation (red circle). (b) Sagittal CBCT sections confirmed the untreated disto-buccal root canal (blue arrows).

With the patient's consent, a small volume cone-beam computed tomography (CBCT) scan (ProMax 3Ds ; Planmeca OY, Helsinki, Finland) was taken of the area of interest. The cross-sectioned images of the area of interest confirmed an untreated disto-buccal root canal, a radiolucent lesion associated with the distal root, and a furcal perforation (*Fig.2a,b*).

After local anaesthesia and rubber dam isolation, the coronal filling material was removed, and an adequate endodontic access was made. Under microscopic vision, we opened the access cavity and corrected it with ultrasonic tips in order to visualize the open orifices to the root canals and locate the site of the perforation. The disto-buccal root canal was located distally to the perforation (*Fig. 3a*). We removed gutta-percha from the palatal and mesio-buccal root canals, negotiated blockages, and confirmed canal patencies. Then, all the root canals were cleaned, shaped, and packed using warm gutta-percha with a vertical condensation technique (*Fig. 3b-d*).

We dried the furcal perforation with a cotton pellet and packed Biodentine™ into the defect (*Fig. 4a-c*). A hand plugger was used to gently accommodate Biodentine™ inside the defect. Biodentine™ was mixed according to the manufacturer's instructions and allowed to set for 12 min. An endodontic sponge was placed on the set Biodentine™ and the access cavity temporized with IRM® (Dentsply De Trey GmbH,

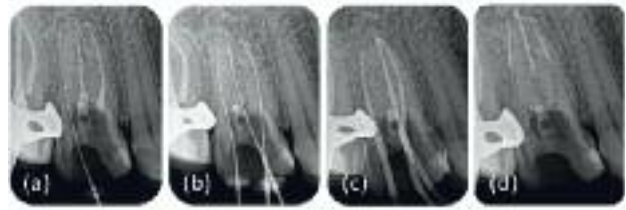

Fig. 3: (a-d) Periapical radiographs showing the entire sequence of the non-surgical treatment.

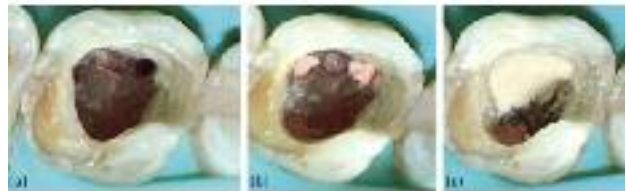

Fig. 4: (a,b) Location of the furcal perforation. (c) Biodentine™ within the access cavity.

Konstanz, Germany) (*Fig. 5a*). Subsequently the access cavity was sealed with a composite (Syntac and Tetric Ceram; Vivadent, Schaan, Liechtenstein). The patient was rescheduled for re-evaluation at 6 and 12 months, whereupon radiographic examination showed no signs of apical periodontitis (*Fig. 5b*), and clinically the patient was totally asymptomatic.

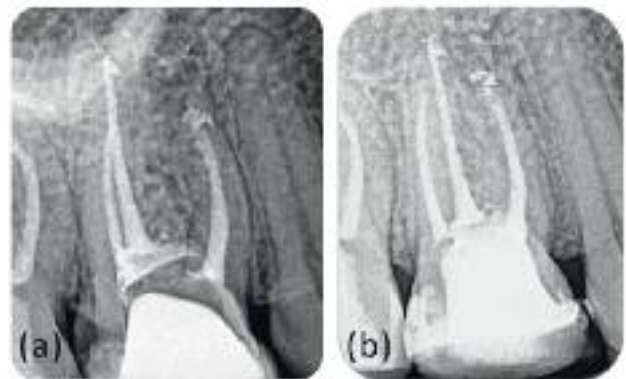


Fig. 5: (a) Completed endodontic retreatment. (b) One-year follow-up radiograph.

Clinical case no.2

A 32-year old female patient was seen in the Department of Restorative Dentistry and Endodontics at the Universitat Internacional de Catalunya (St Cugat del Vallès, Barcelona, Spain) for evaluation and treatment of a maxillary left first molar (# 14). The general anamnesis

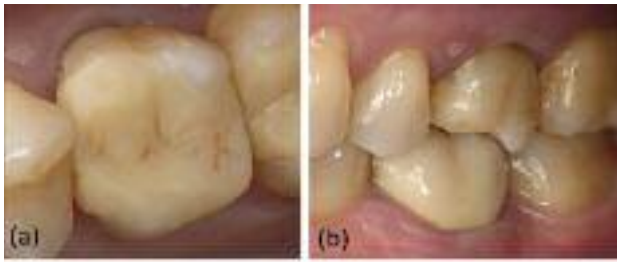

Fig. 6: (a) Tooth #14 with composite resin overlay. (b) Lateral view of tooth #14.

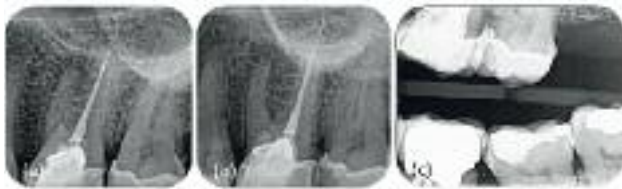

Fig. 7: (a,b) Pre-operative periapical radiographs (parallax technique) with different horizontal angulations. (c) Bite-wing radiograph.

contained no abnormal data. On examination the tooth showed a composite resin overlay (**Fig. 6a,b**). Clinically, the tooth was negative to palpation and percussion; radiographic examination revealed incomplete root canal fillings and signs of periapical radiolucency (**Fig. 7a-c**). Having diagnosed an asymptomatic apical periodontitis we suggested non-surgical treatment. Informed consent was obtained from the patient, and a small volume CBCT was taken using ProMax 3Ds (Planmeca OY, Helsinki, Finland) to reveal the exact location of the untreated root canals. The tooth involved was pinpointed, and the morphology was obtained in coronal, axial and sagittal sections of 0.5mm thickness. The axial and coronal images showed the presence of the mesio-buccal and disto-buccal root canal, as well as a furcal perforation (**Fig. 8a,b**).

After placing a rubber dam and disinfecting the area, we refined the access opening and inspected the pulp chamber floor with a microscope (**Fig. 9a**). Carefully examination with a DG-16 endodontic explorer (Hu-Friedy, Chicago, IL) revealed the canal openings of the disto-buccal and mesio-buccal root. The root canals were negotiated, working length was established using Root ZX apex locator (J. Morita Mfg Corp, Kyoto, Japan), and a radiograph with files in the canals was taken (**Fig. 9b**). The biomechanical instrumentation was performed with Profile




Fig. 8: Small volume CBCT scan (ProMax 3Ds; Planmeca OY, Helsinki, Finland). (a) Axial CBCT sections from the cervical, middle and apical thirds of the tooth #14. Note the presence of the untreated mesio-buccal and disto-buccal root canal. (b) Coronal images showed a furcal perforation (red circle) as well as a periapical radiolucency associated with the mesio-buccal root.

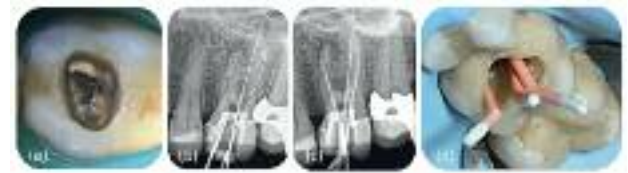

Fig. 9: (a-d) Sequence of the non-surgical treatment.




Fig. 10: (a-c) The perforation (blue arrow) of the pulp chamber floor was covered with Biodentine™. (d) Post-operative periapical radiograph taken immediately after completion of the root canal retreatment and the placement of Biodentine™.

(Dentsply Maillefer, Ballaigues, Switzerland). Gutta-percha cones were used to confirm working lengths (**Fig. 9c,d**). Canal preparation was accompanied by copious irrigation with 4.2% sodium hypochlorite, followed by a final flush with 17% EDTA for 2 minutes and neutralized with 4.2% sodium hypochlorite. The final flushing of the root canals with sodium hypochlorite was performed with ultrasonic passive irrigation for 1 minute. After final irrigation, the root canals were filled using Sytem B heat source (EIE/Analytic Technology, Richmond, WA, USA) (**Fig. 10a,b**). Then, the perforation was dried and Biodentine™ was packed into the defect and allowed to set for 12 min (**Fig. 10c,d**). Finally, we placed zinc oxide-eugenol material (IRM® cement; Dentsply De Trey GmbH, Konstanz, Germany) above the Biodentine™ to prevent its displacement.

The patient returned 3 days later to have the access permanently sealed with a light-cured composite resin (Enamel Plus HRI; Micerium, Avegno, Italy). The tooth was asymptomatic at

12-month recall examination and periapical radiographs showed a successful resolution of the periradicular lesion (*Fig. 11a, b*).

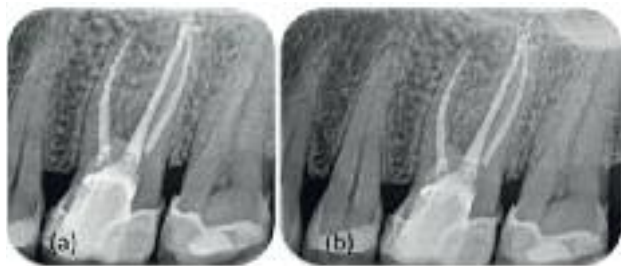

Fig. 11: (a,b) At 12 months, the radiographic examination revealed a successful resolution of the periradicular lesion.

Conclusions

- Furcal perforation may be the consequence of procedural error or pathologic process such as caries and root resorption.
- When left untreated, perforations on the floor of the pulp chamber have the worst prognoses.
- The use of calcium silicate-based cement (Biodentine™) to seal furcal root perforation seems to be associated with a good short-term clinical outcome. The long term follow up of these cases is in progress.

Authors:

Adriana Gómez-Rojas
Guillermo Doria Jaureguizar
Francesc Abella Sans

Department of Restorative Dentistry and Endodontics
 Universitat Internacional de Catalunya (Spain)



Francesc Abella Sans Master of Endodontics - Universitat Internacional de Catalunya (2005-2007)
 Oral rehabilitation and implant dentistry - Universidad de Sevilla (2009-2010)
 Director of the Master of Endodontics (online) since 2009
 Coordinator of the Master of Endodontics (since 2012)
 National and International Journal Publications

References

01. Asgary S, Shahabi S, Jafarzadeh T, Amini S, Kheirieh S. The properties of a new endodontic material. *J Endod* 2008;34:990-3.
02. Gandolfi MG, Pagani S, Perut F, Ciapetti G, Baldini N, Mongiorgi R, Prati C. Innovative silicate-based cements for endodontics: a study of osteoblast-like cell response. *J Biomed Mater Res A* 2008;87:477-86.
03. Gomes-Filho JE, Rodrigues G, Watanabe S, Estrada Bernabé PF, Lodi CS, Gomes AC, Faria MD, Domingos Dos Santos A, Silos Moraes JC. Evaluation of the tissue reaction to fast endodontic cement (CER) and Angelus MTA. *J Endod* 2009;35:1377-80.
04. Johnson BR. Considerations in the selection of a root-end filling material. *Oral Surg Oral Med Oral Pathol Oral Radiol Endod* 1999;87:398-404.
05. Pairokh M, Torabinejad M. Mineral trioxide aggregate: a comprehensive literature review –part III: clinical applications, drawbacks, and mechanism of action. *J Endod* 2010;36:400-13.
06. Torabinejad M, Hong CU, McDonald F, Pitt Ford TR. Physical and chemical properties of a new root-end filling material. *J Endod* 1995;21:349-53.
07. Dammaschke T, Gerth HU, Zuchner H, Schafer E. Chemical and physical surface and bulk material characterization of White ProRoot MTA and two Portland cements. *Dent Mater* 2005;21:731-8.
08. Goldberg M, Pradelle-Plasse N, Tran XV, Colon P, Laurent P, Aubut V, About I, Boukpepsi T, Septier D. Emerging trends in (bio)material researches. In: Goldberg M, ed. *Biocompatibility or cytotoxic effects of dental composites*. Oxford, UK: Coxmoor Publishing, 2009 pp. 181-203.
09. Laurent P, Camps, About I. Biodentine™ induces TGF-β1 release from human pulp cells and early dental pulp mineralization. *Int Endod J* 2012;45:439-48.

Vital Pulp Therapy / Pulp Capping with Biodentine™

Dr Godfrey Cutts
Private practice, United Kingdom

Case Report no.1

A 25 year old female patient who had attended for regular treatment since a child, was highly motivated and had good oral hygiene was referred for possible endodontic treatment to 37. Upon examination the tooth was asymptomatic and gave normal vital responses to thermal and electronic pulp testing. The pre-operative radiograph (*Fig. 1*) demonstrated an extensive distal carious lesion with no evidence of apical periodontitis.

Local anaesthetic was administered, the tooth isolated with rubber dam and the caries excavated which revealed an exposure of the distal pulp horn (*Fig. 2*) with normal vital pulp tissue. The cavity was irrigated with 3% sodium hypochlorite for 30 seconds and then rinsed thoroughly with copious amounts of sterile water. The cavity was then dried taking care to not desiccate the pulp.

Biodentine™ was mixed according to the manufacturers' instructions and using a Thymozin instrument a thin layer of material was placed

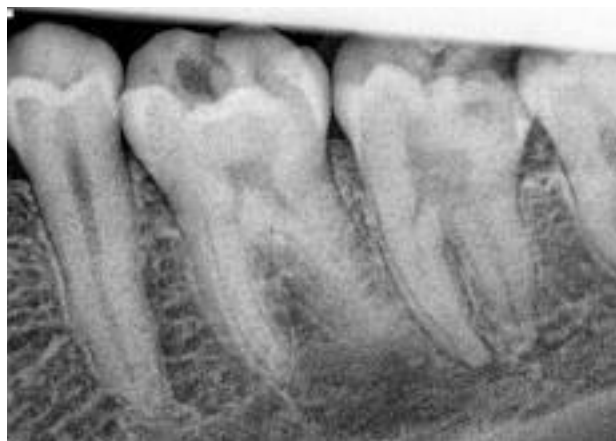

Fig. 1

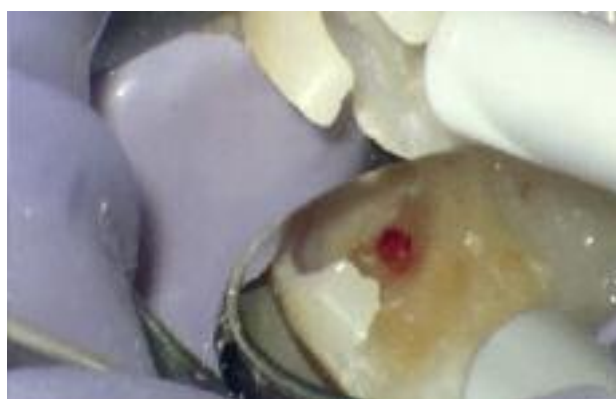

Fig. 2

over the exposed pulp taking care to avoid creating pressure on the pulp. (*Fig. 3 & 4*) This

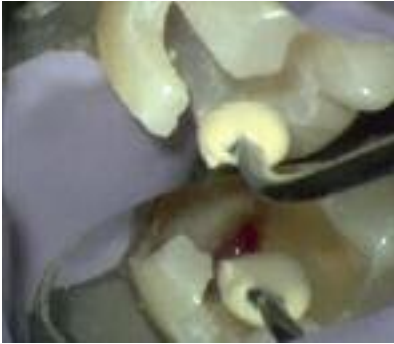

Fig. 3

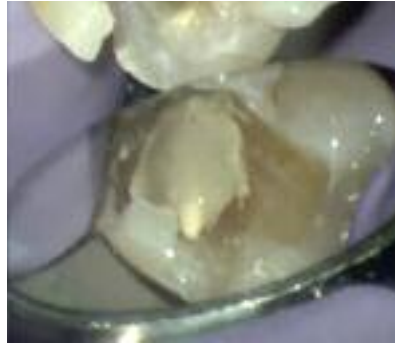

Fig. 4

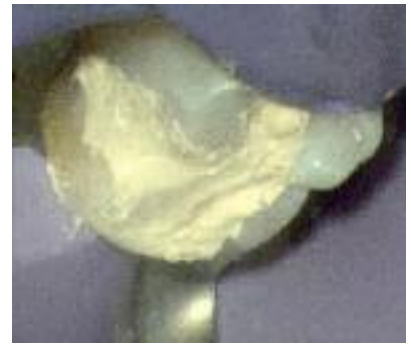


Fig. 5

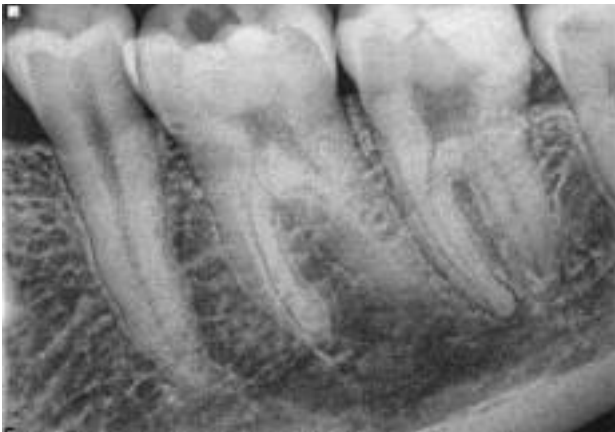

Fig. 6

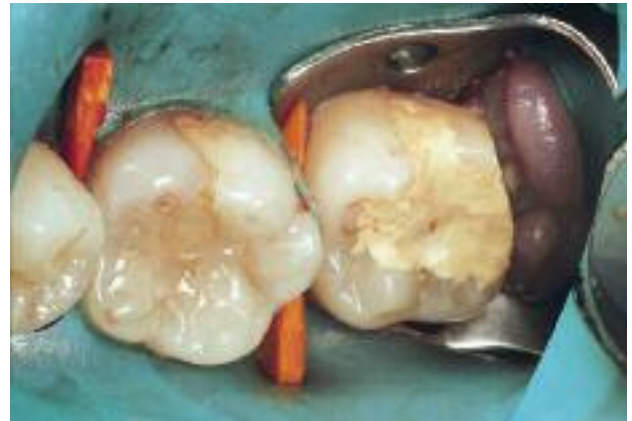

Fig. 7

material was then allowed to set for 10 minutes. When the Biodentine™ had set a second mix was used to bulk fill the cavity to act as a temporary restoration. (Fig. 5)

The post-operative radiograph demonstrates that the Biodentine™ has not encroached into the pulp space. (Fig. 6)

At a subsequent appointment some two weeks later my colleague Jose Antonio Victoria Ortega carried out a conventional cavity preparation leaving a layer of Biodentine™ over the exposed pulp and provided bonded composite restorations. (Fig. 7, 8, 9)

Some six months later the tooth gave normal vital responses to thermal and electronic pulp testing and will be monitored on an annual basis.

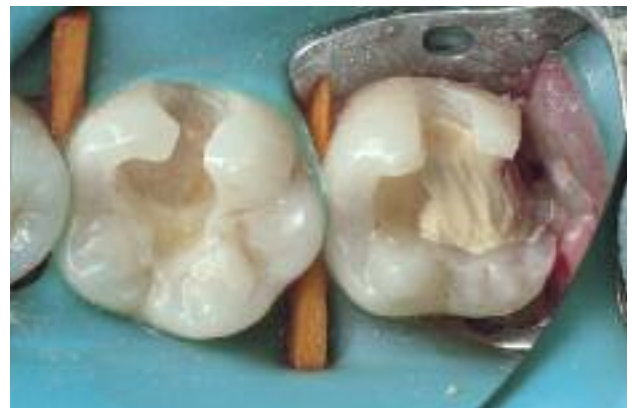

Fig. 8

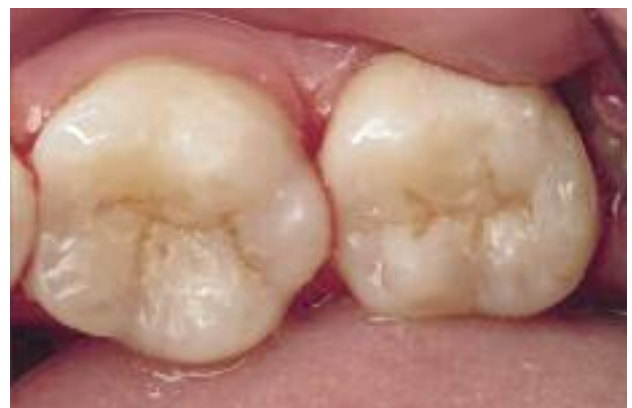

Fig. 9

Case Report no.2

A 30 year old male patient referred with internal resorption (pink spot) 11 (Fig. 10)

The pre-operative radiograph (Fig. 11) demonstrates a mesial composite restoration with the resorption extending to the restoration.

Local anaesthetic was administered and the tooth isolated with rubber dam. The composite restoration was removed which revealed the extent of the lesion.(Fig. 12) Pulpotomy was performed, the cavity irrigated with 3% sodium hypochlorite, rinsed thoroughly with sterile water and the pulp gently dried with sterile paper points.

Biodentine™ was mixed according to the manufacturers instructions and a layer of this material placed over the exposed pulp using a Thymozin instrument and allowed to set for 10 minutes. (Fig. 13) When the Biodentine™ had set a layer of GIC applied followed by a bonded composite restoration.

At follow up six months later the tooth responded normally to thermal and electronic pulp test and annual review is planned.

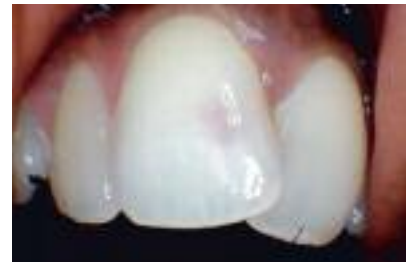

Fig. 10

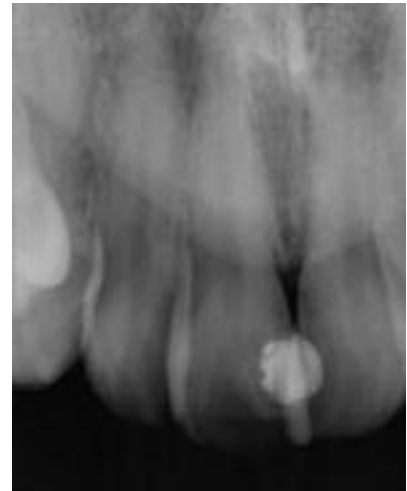

Fig. 11

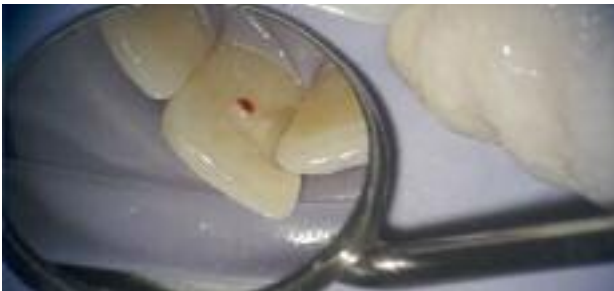

Fig. 12

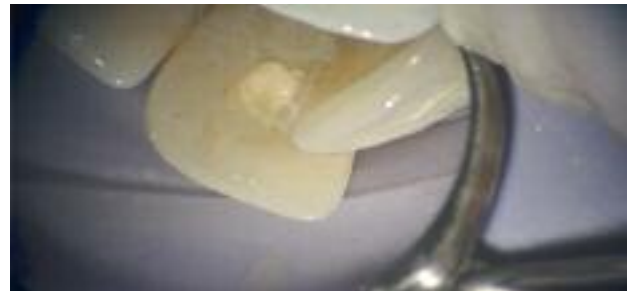

Fig. 13

Download the complete series

Septodont
Case Studies
Collection

www.septodont.com



Case Report no.3

A nine year old male was referred with trauma to 11 and exposure of the mesial pulp horn. (Fig. 14)

The radiograph demonstrated a juvenile tooth with immature open apex (Fig. 15) the aim of the treatment is to preserve vitality and promote formation of the apex.

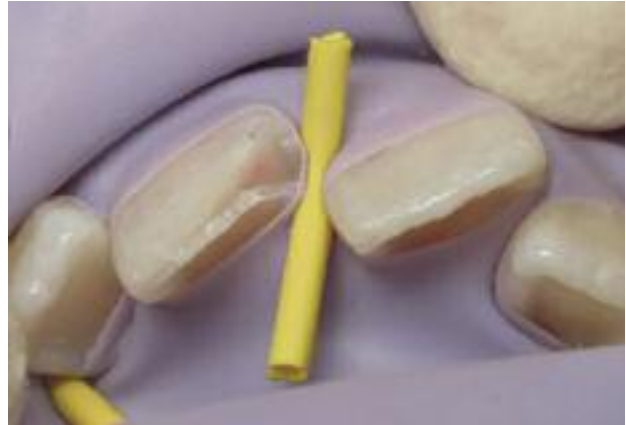

Fig. 14

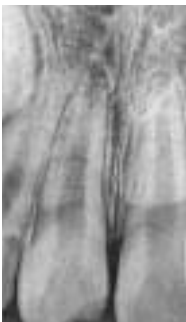

Fig. 15

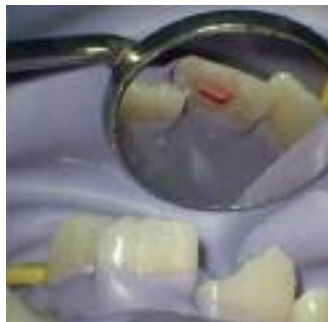

Fig. 16

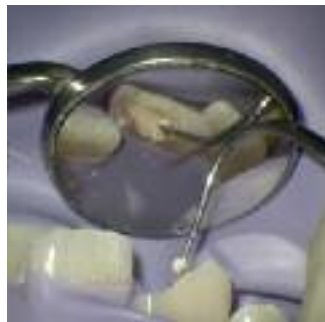

Fig. 17

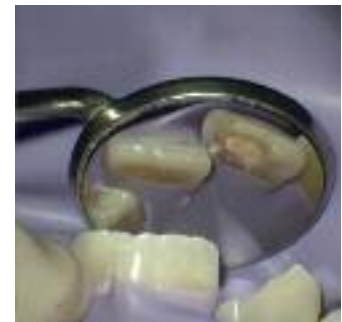

Fig. 18

Local anaesthetic was administered and the tooth isolated with rubber dam. Pulpotomy was performed, (Fig. 16) Biodentine™ placed passively on the pulp stump with a Thymozin instrument (Fig. 17) and allowed to set. (Fig. 18) GIC was placed over the set Biodentine™. A cosmetic repair will be provided at a later date.

The vitality of the tooth will be monitored at three months initially, then at six monthly intervals with radiographic examination every twelve months.



Author: Godfrey Cutts LDS Dunelm

Graduated from the Sutherland Dental School, Newcastle upon Tyne in 1961. In general practice as a GDP in Nuneaton Warwickshire from 1964 until the present day. In 1968 the practice was sold to Oasis Dental Care and has held posts with the company as Clinical Director and Clinical Advisor.

Has a special interest in endodontics and has attended numerous courses including those held at the Eastman Dental Institute and is a member of the British Endodontic Society attending their meetings on a regular basis.

In the past eight years he has organised and lectured at hands on courses for GDP's at venues around the country.

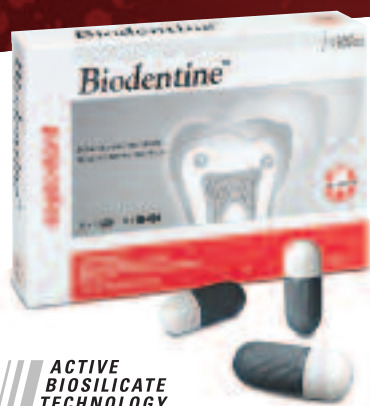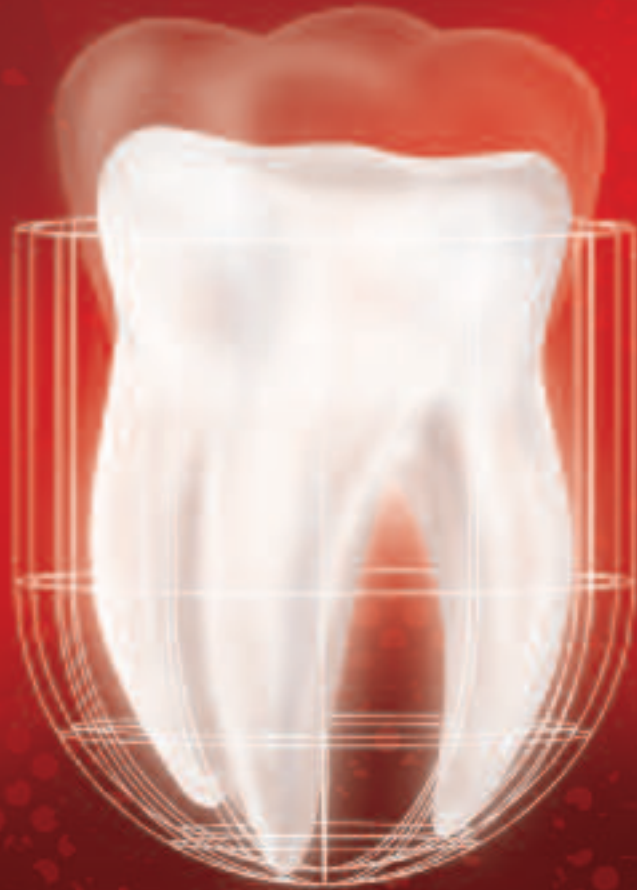Has an active interest in developing new instruments, materials and protocols for their use to enhance treatment outcomes.

In 2005 he filmed and produced the instructional DVD for the use of RaCe Ni-Ti files.

Currently he has a successful endodontic referral practice, treating some 500 cases a year, where practitioners from some fifty miles around refer patients for initial treatments, re-treatments and apical micro-surgery.

Biodentine™

The first and only dentin in a capsule



ACTIVE
BIOSILICATE
TECHNOLOGY

As the **first all-in-one** biocompatible and bioactive **dentin substitute**, Biodentine™ fully replaces dentin wherever it's damaged.

Biodentine™ helps the remineralization of dentin, preserves the pulp vitality and promotes pulp healing. It replaces dentin with similar biological and mechanical properties.

Improving on **Biodentine™** clinical implementation, you can now bond the composite onto Biodentine™ in the same visit and perform the **full restoration in a single session**.

To enjoy the clinical benefits of the first and only dentin in a capsule, ask your dental distributor for Biodentine™.



Learn more with
the Biodentine™ brochure





The Dental Pharmaceutical Company

INNOVATIVE, SAFE AND EFFECTIVE SOLUTIONS FOR DENTISTRY WORLDWIDE